

AIFIMM Formation

Provider CPD 21418 (UK)

CE Broker ID 50-54885 (Florida USA)

Provider ECM 1701 (IT)

www.mskbiomechanics.com

Spinal Column in the Sagittal Plane – Part I Biomechanical Foundations and Cranio-Cervico-Thoracic Organization

Mauro Lastrico, PT – Laura Manni, PT

Editorial Note

This article constitutes Part I of a single chapter dedicated to the biomechanical analysis of the spinal column in the sagittal plane.

For technical publication reasons, the content has been divided into two consecutive articles that should be read as a continuous whole.

The considerations that follow represent the application of the physical and vector principles described in the previous chapters.

The sagittal plane is the reference plane for the analysis of the physiological curves of the spine and their equilibrium relationships.

The aim is to describe the individual segments and the muscles involved, in order to understand how the distribution of muscular forces determines spinal configuration and how variations in these forces modify the articular sequence.

By identifying the dominant vectors and the mechanical resultants underlying changes in the physiological curves of the vertebral sinusoid, district analysis remains consistent with the general physical model, showing how the same laws—tissue elasticity, force moments, and the balance between G and R forces—find concrete expression in the human body.

1. Introduction to vector analysis in the sagittal plane

This chapter analyses the action of the muscles acting symmetrically on both sides of the spinal column and their effects on the vertebral sinusoid in the sagittal plane.

Vector analysis will make it possible to identify the muscular dominances present in each segment and the ways in which antagonist muscles attempt to balance the dominant forces.

Analysis in the sagittal plane does not represent a two-dimensional reduction of the system's complexity, but rather an analytical tool that allows the dominant vector components within a three-dimensional behaviour to be isolated.

1.1 The myofunctional subdivision

By observing the anatomical arrangement of the muscles influencing the cranium, spinal column, and pelvis, it becomes clear that muscular insertions do not respect anatomical boundaries, but instead create functional units involving several vertebral segments.

This observation leads to the addition of a myofunctional subdivision alongside the anatomical classification, divided as follows:

- Cranio-cervico-thoracic lordosis: extending from the cranium to the spinous process of T3
- Thoracic kyphosis: extending from the spinous process of T4 to that of T6
- Thoraco-lumbo-sacral lordosis: extending from the spinous process of T7 to the sacrum

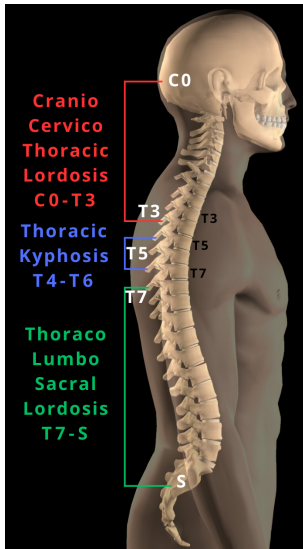


Fig. 01 - Myofunctional subdivision of the spinal column

1.2 The biomechanical rationale of the subdivision

Extension of cervical lordosis to T3

The anatomical lordosis from C1 to C7 is extended muscularly to T3 through the action of specific muscle groups.

Posteriorly:

- Trapezius (upper fibres), inserting onto the scapula
- Levator scapulae, connecting the cervical vertebrae to the scapula
- Paravertebral muscles (including splenius, semispinalis, and multifidus)

The superomedial angle of the scapula is anatomically positioned at the level of T3, creating a continuous functional unit.

Anteriorly:

- Anterior paravertebral muscles inserting down to T3 (longus capitis, longus colli, and rectus capitis)
- Scalenes, connecting the cervical vertebrae to the first ribs
- Sternocleidomastoid muscles

This muscular extension explains why cervical problems may present with symptoms involving the upper thoracic region as well.

Extension of lumbar lordosis to T7

Lumbar lordosis is extended to T7 mainly by the insertions of the latissimus dorsi, which spans from the lumbar vertebrae to the mid-lower thoracic vertebrae.

Because of its extent and vector power, this muscle functionally unifies the entire segment from T7 to the sacrum.

Thoracic kyphosis as a transitional zone

This analysis shows that the physiological kyphosis with its apex at T5 is the posterior junction of two curves oriented anteriorly. On this short segment, the middle fibres of the trapezius and the rhomboids act predominantly.

1.3 The biomechanical function of the curves

Functionally, the vertebral sinusoid serves to absorb vertical loads.

If the spine were straight, it would be subjected to greater compressive damage due to the direct effect of compression forces.

The presence of curves transforms vertical compressive forces into more manageable components, distributing loads throughout the whole structure.

The small posterior curve from T4 to T6 is simply the geometric junction between the two anteriorly oriented curves, creating a shock-absorbing system for stresses along the vertical axis.

1.4 The ontogenetic development of the curves

The development of vertebral curves during growth confirms this functional view:

1. The newborn presents a totally kyphotic spinal column (primary curve).
2. During growth, the infant uses the muscles between the cranium and T3 to create the cervico-thoracic lordosis that allows head control and horizontal vision.
3. Subsequently, the muscles between T7 and the sacrum are used to create the thoraco-lumbo-sacral lordosis that allows the achievement of upright posture.

This sequential development demonstrates that vertebral curves are the result of muscular action and not mere anatomical adaptations.

1.5 Implications for clinical analysis

In the following analysis, we will examine the possible modifications of the vertebral segments caused by shortening of the muscles acting on each functional unit.

Clinical assessment tools:

- Specific investigations for the assessment of spinal curves
- Palpation of the vertebrae over the spinous processes to identify curve transitions and areas of greatest tension
- Assessment of disc compressions through palpation of the spinous processes

Guiding principles for interpretation:

1. any alteration in one of the three functional units may influence the others;
2. muscular shortenings modify the curves according to predictable patterns;
3. symptoms may appear at a distance from the primary biomechanical cause;
4. the therapeutic approach should consider that intervention on the symptomatic segment alone may be insufficient and that the functional unit as a whole may need to be assessed.

This integrated view of the spinal column as a system of interconnected functional units forms the basis for a correct biomechanical interpretation of vertebral clinical conditions.

2. Cranio-cervico-thoracic lordosis (C0-T3)

2.1 Anatomical and functional characteristics

The cranio-cervico-thoracic segment presents a specific feature compared with the rest of the spinal column: it is the only segment in which paravertebral muscles are present with dual insertion, both anteriorly (anterior neck muscles) and posteriorly (posterior paravertebral muscles). This anatomical peculiarity determines complex and distinctive biomechanical mechanisms in this region.

As already observed, the muscular support for the extension of cervical lordosis to T3 is produced mainly by the anterior neck muscles inserting down to T3: rectus capitis anterior, longus capitis, and longus colli.

2.2 Acting muscle groups

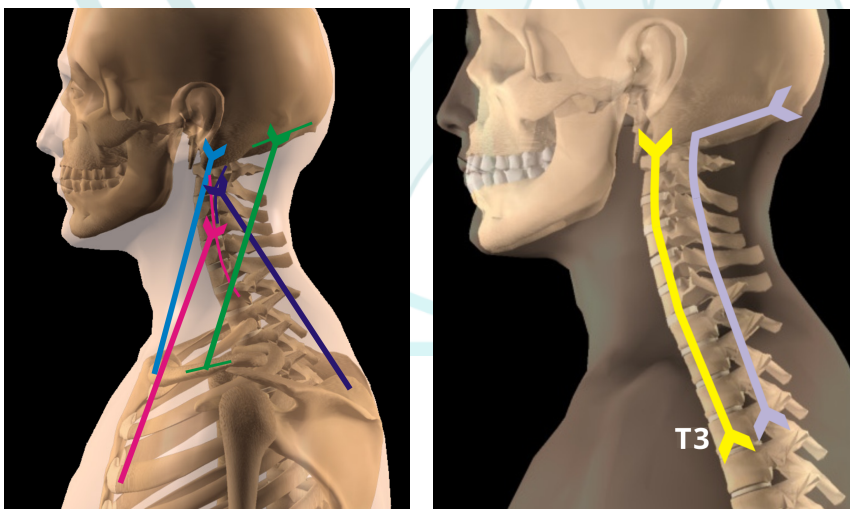
Anteriorly:

- Scalenes and sternocleidomastoids
- Anterior neck muscles (rectus capitis anterior, longus capitis, longus colli)

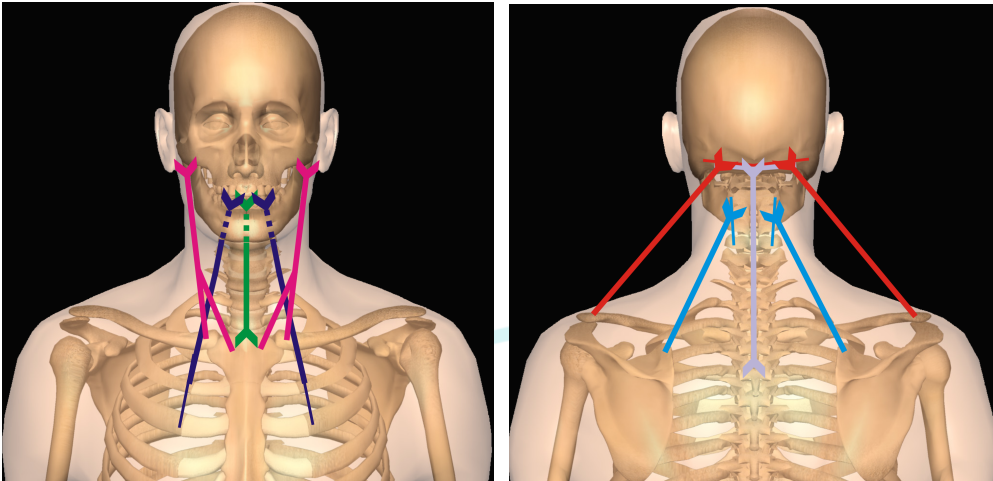
Posteriorly:

- Posterior paravertebral muscles
- Levator scapulae
- Upper fibres of the trapezius

In the following figures, the force lines of the individual muscles are represented, considering the cranial and vertebral insertions as the mobile point.



Figures 2 and 3: Muscles represented - sternocleidomastoid: light blue; levator scapulae: blue; upper trapezius fibres: green; scalenes: magenta; anterior neck muscles: yellow; paravertebrals: light purple



Figures 4 and 5: Muscles represented - sternocleidomastoids: magenta; anterior neck muscles: green; upper trapezius fibres: red; levator scapulae: blue; paravertebrals: light purple; scalenes: blue

2.3 Vector analysis of the posterior muscles

Increased basal tone and subsequent shortening of the posterior muscles produce two main effects:

1. Posterior flexion of the cranium through the action of:
 - Direct: paravertebrals and upper trapezius fibres
 - Indirect: levator scapulae
2. Increase in cervical lordosis through the action of:
 - Direct: paravertebrals and levator scapulae
 - Indirect: upper trapezius fibres

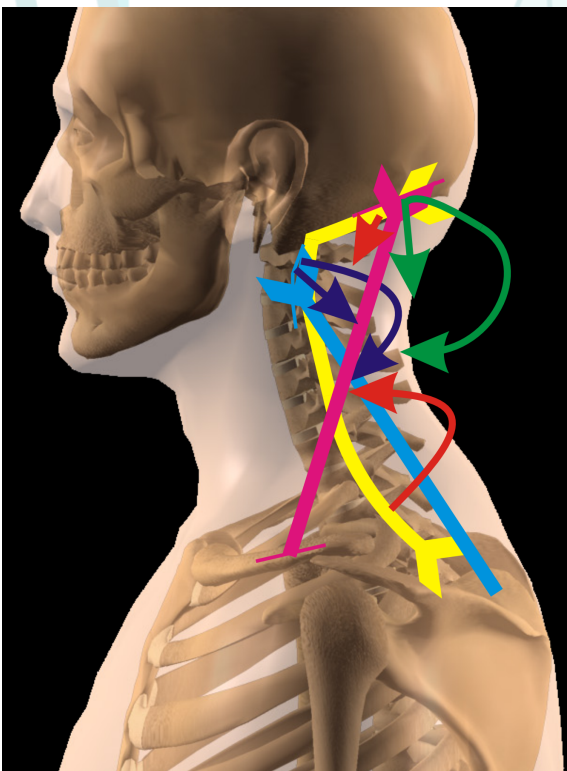


Figure 6: Actions of the posterior muscles - the upper trapezius fibres (green arrows) posteriorly flex the cranium and, by mechanical resultant, increase vertebral lordosis; the levator scapulae (blue arrows) posteriorly flex the vertebrae from C1 to C4 and, by mechanical resultant, increase cervical lordosis as a whole; the paravertebrals (red arrows) posteriorly flex the cranium and increase the cervico-thoracic lordosis from C1 to T3.

2.4 Vector analysis of the anterior muscles

The action of the anterior muscles varies according to the position of the cranium and the existing cervical curve.

The involvement of the anterior muscles creates different patterns, depending on whether the cranium behaves as a fixed point or a mobile point.

With the cranium as a fixed point

Situation 1: Physiological lordosis

With the occiput on the same vertical line as the thoracic kyphosis and the cervical spine in physiological lordosis, the sternocleidomastoids, in their bilateral action, flex the cranium anteriorly, mechanically resulting in a reduction of lordosis.

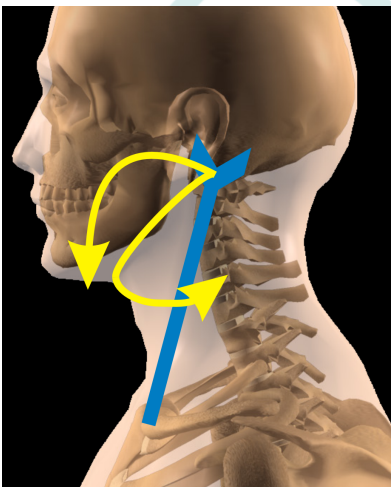


Figure 7: With the occiput aligned with the thoracic vertebrae and the cervical spine in physiological lordosis, the sternocleidomastoids, with their force line passing anterior to the mastoid, flex the cranium anteriorly and, by mechanical resultant, reduce cervical lordosis. Sternocleidomastoid: blu

Situation 2: Pre-existing hyperlordosis

If, however, the position of the cranium is in posterior flexion, the force line of the sternocleidomastoids passes behind the mastoid, causing inversion of their action.

They will posteriorly flex the cranium, contributing to the increase in lordosis together with the scalenes.

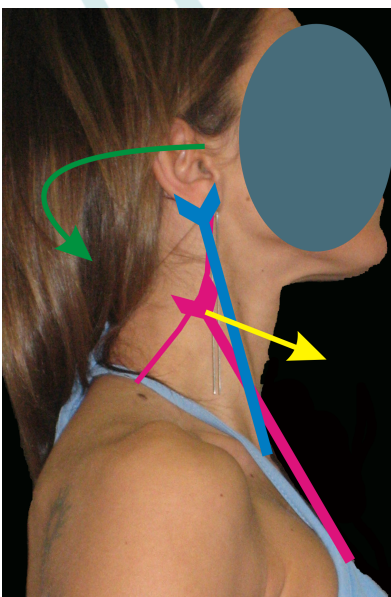


Figure 8: With the cranium as a fixed point and in posterior flexion, the sternocleidomastoids, with their force line passing behind the mastoid, invert their action and posteriorly flex the cranium, increasing cervical lordosis. Cervical lordosis is also increased by the action of the scalenes. Sternocleidomastoid: blue; scalenes: magenta

Behaviour of the anterior neck muscles

The anterior neck muscles (rectus capitis anterior, longus capitis, and longus colli) show a similar inversion of action.

When the spinal column is in physiological lordosis and the occiput is aligned with the thoracic vertebrae, their force line passes anterior to the sagittal midline of the vertebrae.

In this case, their action is to straighten the cervical segment.

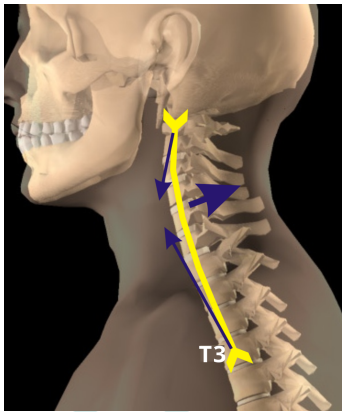
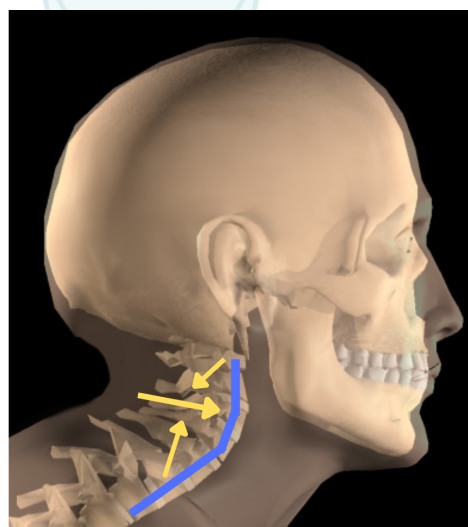
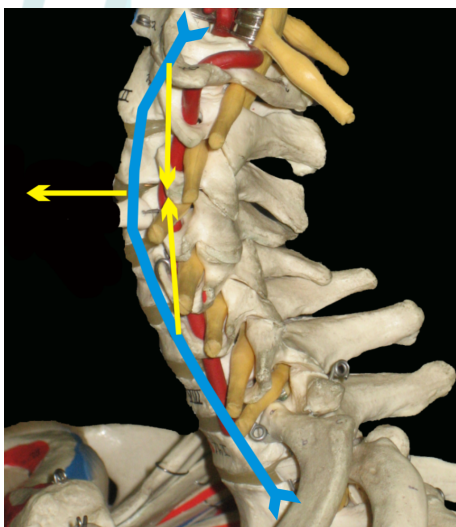


Figure 9: Occiput aligned with the thoracic vertebrae and cervico-thoracic spine in physiological lordosis. The anterior neck muscles, with their force line passing anterior to the sagittal midline of the vertebral bodies, reduce cervico-thoracic lordosis. Anterior neck muscles: yellow

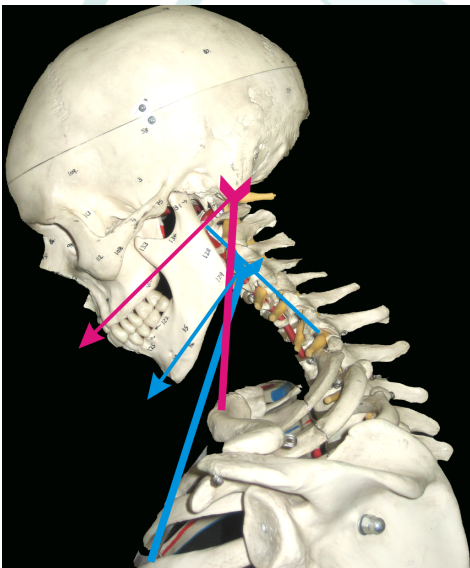
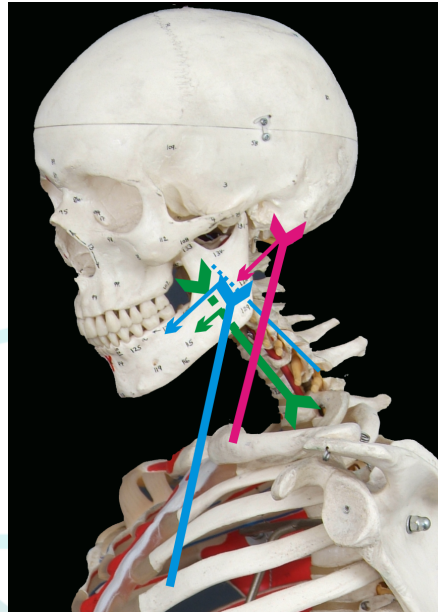
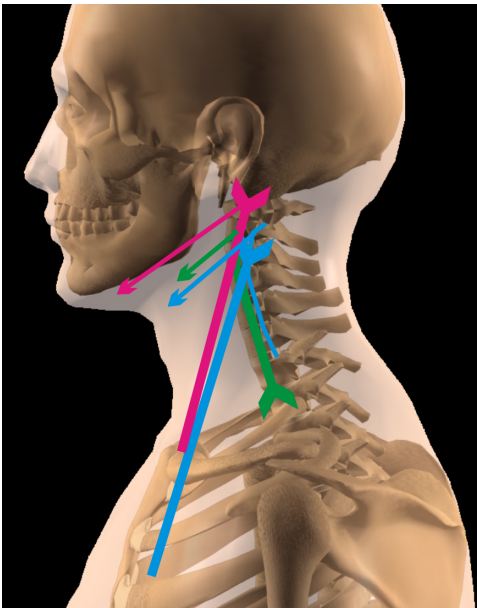
If the spine is in hyperlordosis, the force line shifts posterior to the sagittal midline and the action becomes the opposite: the anterior neck muscles will increase lordosis.



Figures 10 and 11: Cervical spine in increased lordosis. In this case, the anterior neck muscles, with their force line passing posterior to the sagittal midline of the vertebral bodies, increase cervico-thoracic lordosis. Anterior neck muscles: blue

With the cranium as a mobile point

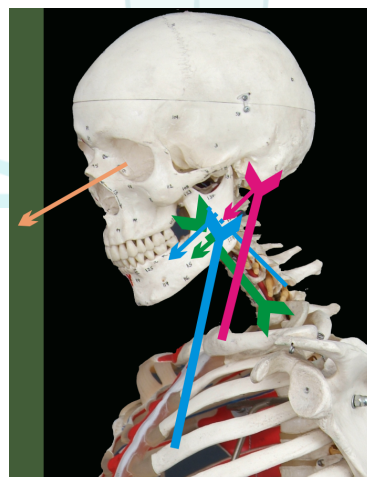
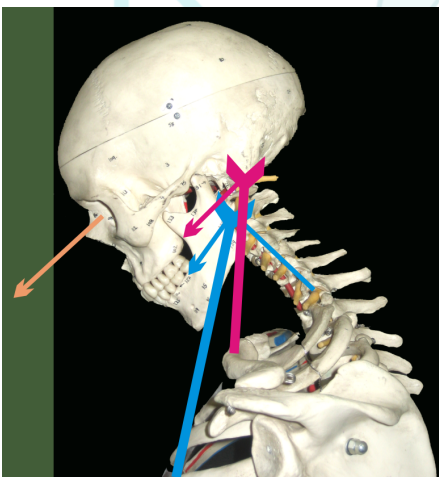
When, in order to maintain balance and visual orientation, the central nervous system requires it, the sternocleidomastoids, scalenes, and anterior neck muscles enter into summation and synergy of action, producing anterior projection of the head and straightening the cervical spine obliquely forward.

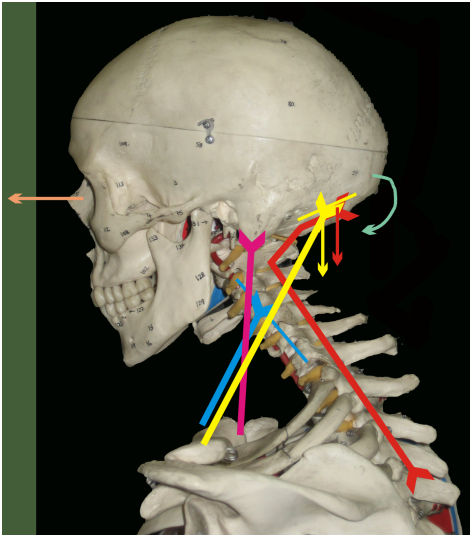


Figures 12, 13 and 14: Cranium as a mobile point - sternocleidomastoids, scalenes, and anterior neck muscles enter into summation of action and project the cranium and the first cervical vertebrae anteriorly. The cervical spine assumes a straight and obliquely forward course. Anterior neck muscles: green; scalenes: blue; sternocleidomastoid: magenta

Compensation for visual control

Recovery of gaze orientation then occurs through contraction of the posterior paravertebral muscles and the upper trapezius fibres, which posteriorly flex the cranium.





Figures 15, 16 and 17: If sternocleidomastoids, scalenes, and anterior neck muscles project the cranium and first cervical vertebrae anteriorly, the gaze is directed downward. To recover horizontal gaze orientation, the paravertebrals and upper trapezius fibres posteriorly flex the cranium. Anterior neck muscles: green; sternocleidomastoid: magenta; scalenes: blue; paravertebrals: red; upper trapezius fibres: yellow

2.5 Control of cranial position

Balance control reflexes

Balance control reflexes interact with one another in order to maintain the position of the cranium well oriented in space, with the palpebral fissure as horizontal as possible, implying the involvement of all crania-cervico-scapular muscles.

From a vector perspective, the muscles that increase cervical lordosis, directly or indirectly, are dominant, and their shortening also causes posterior flexion of the head, interfering with vision.

The compensatory mechanism

As already observed, in order to restore the horizontal orientation of the eyes, the anterior muscles of the cervico-thoracic spine enter into excessive tension and, by “unrolling” the spine forward, bring the cranium anteriorly.

The sternocleidomastoids also directly contribute to this anterior displacement.

Horizontal vision is thus restored, but the cranial centre of gravity is no longer aligned with the vertebral body of T3.

Calculation of the force moment

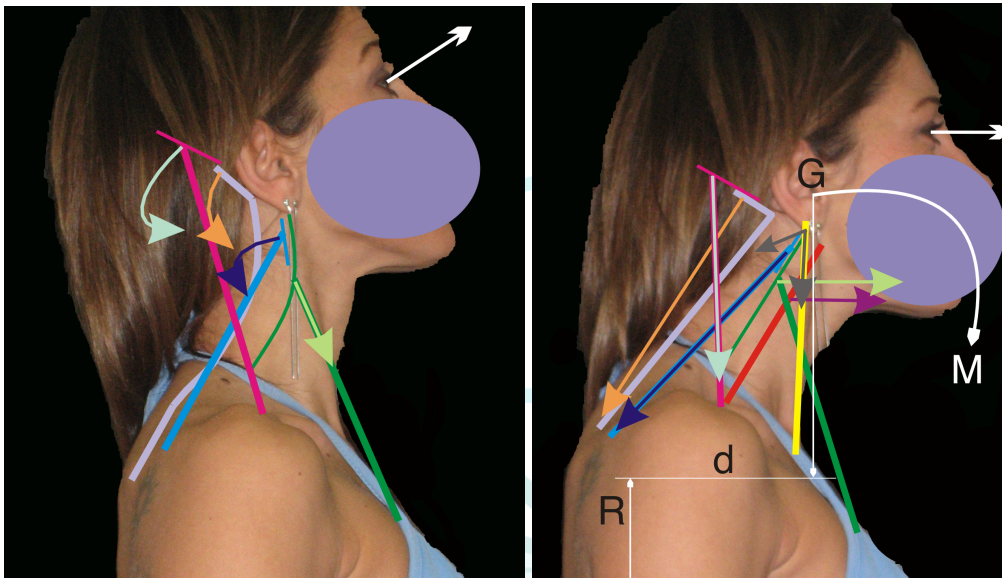
In the presence of two equal and opposite forces aligned vertically (the weight of the cranium applied at its centre of gravity and the counterthrust along the spine, for example at the level of T3), a couple is generated that produces a force moment equal to the product of the force and the distance separating them.

If the cranium weighs about 5 kg and the distance between the cranial centre of gravity (near the acoustic meatus) and the point at which the vertebral counterthrust is considered to be applied (for example the spinous process of T3) is 3 cm, the extensor moment required will be:

$$M = F \times d = 5 \text{ kg} \times 3 \text{ cm} = 15 \text{ kg}$$

The force that the posterior muscles must develop is not 15 kg, but depends on their lever arm relative to the axis of rotation: if their lever arm is, for example, 2 cm, the required force will be about $15/2 = 7.5 \text{ kg}$.

What is clinically relevant is not the absolute value, but the fact that, as the distance between the cranial centre of gravity and the point of counterthrust increases, the moment to be balanced grows, and therefore the force demand on the extensor muscles increases.



Figures 18 and 19: If the posterior muscles primarily enter into shortening, the cranium is in posterior flexion and the gaze is directed upward. To regain horizontal gaze, the muscles located anterior to the spine project the cranium and first cervical vertebrae forward. With the cranium displaced anteriorly, the posterior muscles must further increase their tension to balance the force moment M . Paravertebrals: light purple; upper trapezius fibres: magenta; scalenes: green; anterior neck muscles: red; levator scapulae: blue; sternocleidomastoid: yellow

2.6 Interpretation of radiographic patterns

Oblique forward straightening

In some radiographic patterns, straightening of the cervical spine is evident, with an obliquely forward course.

This may express the resultant primarily produced by the anterior muscles, which shift the cranium forward with the gaze directed toward the ground.

Recovery of horizontal vision will then be carried out by the head extensors.

Vertical straightening

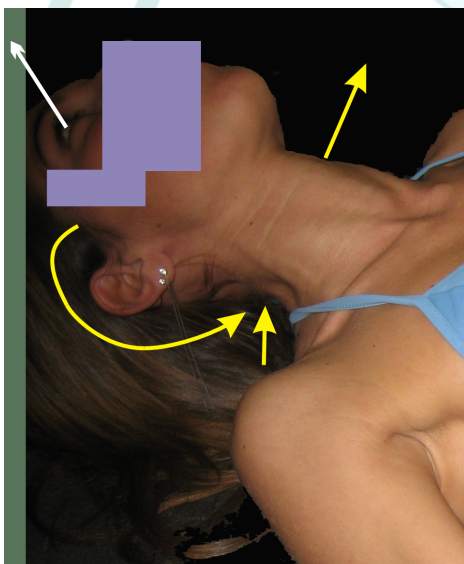
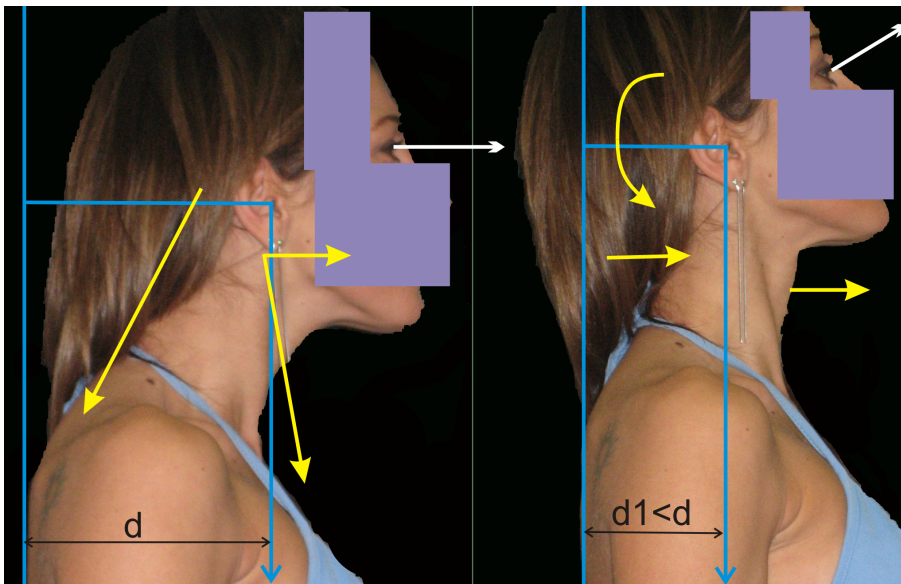
When, on radiography, the spine appears straightened and vertical, since the pattern is incompatible with the action of muscles acting locally, the straightening is the resultant of the reduction in physiological thoracic kyphosis with its apex at T5, caused by thoracic paravertebrals and scapular adductors.

By the term straightening, we do not necessarily mean a structural loss of the curve, but rather a geometric configuration resulting from the balance, or imbalance, of the muscular vectors acting on the vertebral segments.

Diagnostic test

Even when the cervical spine appears straightened and oblique, the cause of the pattern is often hyperlordosis. In fact, when an attempt is made to bring the cranium back onto the vertical line of

the thoracic kyphosis—passively, actively, or by positioning the patient supine—the resulting co-contraction of all the muscles acting on the cervical spine will reveal the increase in lordosis.



Figures 20 and 21: Control comparison - habitual posture on the left and posterior displacement of the cranium on the right. Active posterior displacement of the cranium compared with the habitual condition causes the cervical spine to shift from straightening in an oblique direction to hyperlordosis, with loss of horizontal gaze. A similar effect is seen when the patient is placed supine. In both cases, straightening can be “read” as an adaptive functional response to a primary condition of hyperlordosis.

2.7 Biomechanical consequences on the intervertebral discs

Whether the cervico-thoracic spine shows increased lordosis or straightening with anterior head projection, the G forces and the R reactions, applied to the cranium and the individual vertebrae, generate force moments on the vertebral segments and compressions with their g and r components on the intervertebral discs.

In hyperlordosis

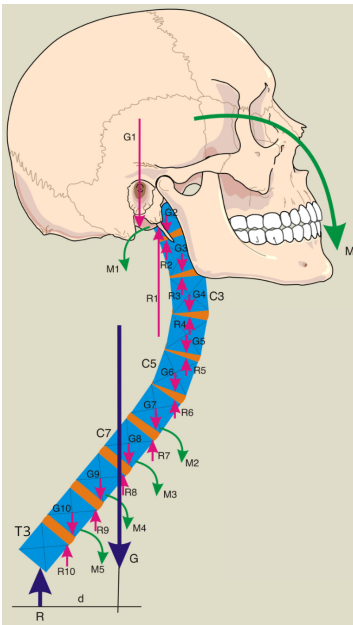


Figure 22: Cervico-thoracic spine with excessive lordosis. The individual G forces applied to each centre of gravity and their R reactions determine the concentration of the g and r components (not represented) at certain points of the articular discs, which will undergo compressive forces. The individual G and R forces also generate force moments at the cranium ($M1$) and at the vertebrae from C6 to T2 ($M2, M3, M4, M5$). The overall G and R forces create the overall force moment M . The posterior muscles, in addition to having produced hyperlordosis, must act at high intensity to balance the force moment M . In doing so, they generate additional posterior mechanical compressions on the articular discs between C2 and C6.

In oblique straightening

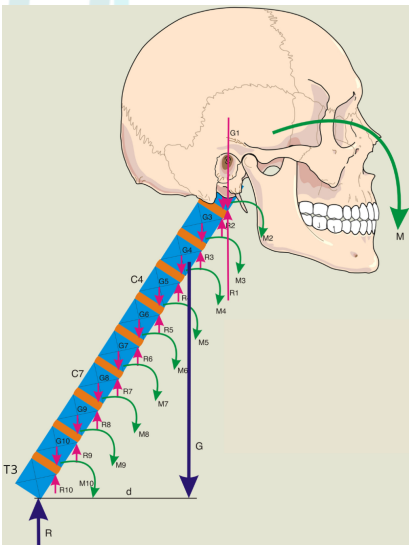


Figure 23: Cervico-thoracic spine straightened and oblique due to the action of the anterior neck muscles, scalenes, and sternocleidomastoids. The individual G and R forces generate the force moments from $M2$ to $M10$. The g and r components create mechanical compressions in the anterior portions of the intervertebral discs. The overall G and R forces generate a force moment M that must be balanced by the tension of the posterior muscles.

2.8 Conclusions and diagnostic tools

Both anterior and posterior muscles act on the crano-cervico-thoracic spine, and their balance determines the correct spatial position of the skeletal segment.

The balancing potential of the anterior muscles is possible only under physiological lordosis conditions.

Its increase, produced by the posterior muscles, which never invert their action, causes inversion of action in the anterior muscles, transforming them into co-agonists of the posterior muscles.

When this happens, in addition to curve changes, compressions are produced on the intervertebral

discs, induced bilaterally by the vertical vector components of the oblique muscles, which sum together.

Diagnostic test: cranial traction

A way to differentiate and identify the dominance in the production of hyperlordosis between anterior and posterior muscles is to perform, in the supine position, a small cranial traction:

- If, with traction, the spine tends to normalize, dominance of the posterior muscles may be hypothesized, and the manoeuvre may also become an effective treatment tool.
- If, with traction, the spine is projected forward, even by a single vertebra or a pair of vertebrae, this is the sign of dominance of the anterior muscles, and repeating the manoeuvre in therapy would aggravate the condition.

References

1. Lastrico M. Clinical Assessment of Muscle Shortening. The CPD Certification Service; 2025.
2. Lastrico M. Body Equilibrium - A Physical-Clinical Interpretation of Human Upright Stability. The CPD Certification Service; 2025.
3. Lastrico M. Vector Analysis in Musculoskeletal Biomechanics - Part 1: Foundations and Clinical Principles. The CPD Certification Service; 2025.
4. Lastrico M. Vector Analysis in Musculoskeletal Biomechanics - Part 2: Clinical Applications and Case Interpretation. The CPD Certification Service; 2025.
5. Sahrman SA. Diagnosis and Treatment of Movement Impairment Syndromes. St. Louis: Mosby; 2002.
6. Knudson D. Fundamentals of Biomechanics. 2nd ed. New York: Springer; 2007.
7. Winter DA. Biomechanics and Motor Control of Human Movement. 4th ed. Hoboken: Wiley; 2009.
8. Lieber RL, Fridén J. Functional and clinical significance of skeletal muscle architecture. *Muscle Nerve*. 2000;23(11):1647-1666.
9. Lieber RL, Ward SR. Skeletal muscle design to meet functional demands. *Philos Trans R Soc Lond B Biol Sci*. 2011;366(1570):1466-1476.
10. Panjabi MM. The stabilizing system of the spine. Part I. Function, dysfunction, adaptation, and enhancement. *J Spinal Disord*. 1992;5(4):383-389.
11. Harrison DD, Janik TJ, Troyanovich SJ, Harrison DE, Colloca CJ. Evaluation of the assumptions used to derive an ideal normal cervical spine model. *J Manipulative Physiol Ther*. 1997;20(4):246-256.
12. Shumway-Cook A, Woollacott M. *Motor Control: Translating Research into Clinical Practice*. 4th ed. Philadelphia: Lippincott Williams & Wilkins; 2012.
13. Dubousset J. Three-dimensional analysis of the scoliotic deformity. In: Weinstein SL, editor. *The Pediatric Spine: Principles and Practice*. New York: Raven Press; 1994. p. 479-496.
14. Page P, Frank CC, Lardner R. *Assessment and Treatment of Muscle Imbalance: The Janda Approach*. Champaign: Human Kinetics; 2010.

15. Vasavada AN, Li S, Delp SL. Influence of muscle morphometry and moment arms on the moment-generating capacity of human neck muscles. *Spine*. 1998;23(4):412-422.
16. Mayoux-Benhamou MA, Revel M, Vallée C. Selective electromyography of dorsal neck muscles in humans. *Exp Brain Res*. 1997;113(2):353-360.
17. Conley MS, Meyer RA, Bloomberg JJ, Feedback DL, Dudley GA. Noninvasive analysis of human neck muscle function. *Spine*. 1995;20(23):2505-2512.
18. Keshner EA. Head-trunk coordination during linear anterior-posterior translations. *J Neurophysiol*. 2003;89(4):1891-1901.
19. Panjabi MM, Crisco JJ, Vasavada A, Oda T, Cholewicki J, Nibu K, Shin E. Mechanical properties of the human cervical spine as shown by three-dimensional load-displacement curves. *Spine*. 2001;26(24):2692-2700.
20. Adams MA, Roughley PJ. What is intervertebral disc degeneration, and what causes it? *Spine*. 2006;31(18):2151-2161.
21. Cholewicki J, McGill SM. Mechanical stability of the in vivo lumbar spine: implications for injury and chronic low back pain. *Clin Biomech*. 1996;11(1):1-15.
22. Cools AM, Declercq GA, Cambier DC, Mahieu NN, Witvrouw EE. Trapezius activity and intramuscular balance during isokinetic exercise in overhead athletes with impingement symptoms. *Scand J Med Sci Sports*. 2007;17(1):25-33.
23. Lee LJ, Coppiteters MW, Hodges PW. Differential activation of the thoracic multifidus and longissimus thoracis during trunk rotation. *Spine*. 2005;30(8):870-876.
24. Kado DM, Huang MH, Karlamangla AS, Barrett-Connor E, Greendale GA. Hyperkyphotic posture predicts mortality in older community-dwelling men and women: a prospective study. *J Am Geriatr Soc*. 2004;52(10):1662-1667.
25. McGill SM. *Low Back Disorders: Evidence-Based Prevention and Rehabilitation*. 3rd ed. Champaign: Human Kinetics; 2016.
26. Hodges PW, Richardson CA. Contraction of the abdominal muscles associated with movement of the lower limb. *Phys Ther*. 1997;77(2):132-142.
27. Adams MA, Hutton WC. The effect of posture on the role of the apophysial joints in resisting intervertebral compressive forces. *J Bone Joint Surg Br*. 1980;62(3):358-362.
28. Roussouly P, Gollogly S, Berthonnaud E, Dimnet J. Classification of the normal variation in the sagittal alignment of the human lumbar spine and pelvis in the standing position. *Spine*. 2005;30(3):346-353.
29. Barker PJ, Guggenheimer KT, Grkovic I, Briggs CA, Jones DC, Thomas CD, Hodges PW. Effects of tensioning the lumbar fasciae on segmental stiffness during flexion and extension: Young Investigator Award winner. *Spine*. 2006;31(4):397-405.